UpToDate®
Official reprint from UpToDate®
www.uptodate.com © 2026 UpToDate, Inc. and/or its affiliates. All Rights Reserved.

Basic airway management in children

AUTHOR: Mark E Ralston, MD, MPH
SECTION EDITOR: Mark I Neuman, MD, MPH
DEPUTY EDITOR: James F Wiley, II, MD, MPH

All topics are updated as new evidence becomes available and our peer review process is complete.

Literature review current through: **Jan 2026.**
This topic last updated: **Aug 16, 2024.**

INTRODUCTION

This topic will review basic airway management in infants and children (including techniques to open the airway and positive pressure ventilation with mouth-to-mouth and a bag-mask device).

The following related topics are discussed separately:

- Advanced airway management in children (see "Technique of emergency endotracheal intubation in children")
- Basic life support in infants and children (see "Pediatric basic life support (BLS) for health care providers")
- Emergency management of foreign body airway obstruction in children (see "Emergency evaluation of acute upper airway obstruction in children")
- The initial assessment and stabilization of critically ill or injured children (see "Initial assessment and stabilization of children with respiratory or circulatory compromise" and "Pediatric advanced life support (PALS)")
- Basic airway management in newborn infants (see "Neonatal resuscitation in the delivery room")

BACKGROUND

Effective airway support is an essential component of successful cardiopulmonary resuscitation (CPR). Respiratory insufficiency leading to respiratory arrest typically precedes cardiac arrest for most children. Survival rates are much higher for children who have been resuscitated from respiratory arrest compared with children who develop cardiac arrest. (See "Pediatric basic life support (BLS) for health care providers", section on 'Epidemiology and survival'.)

ANATOMIC CONSIDERATIONS

A patent airway is a fundamental requirement for effective resuscitation. Anatomic features that make the airways of infants and children more susceptible to obstruction and that must be considered in

order to maintain an adequate airway include the following (see "Emergency airway management in children: Unique pediatric considerations", section on 'Anatomic considerations'):

- **Larynx** – The position of the larynx in infants and children is higher and more anterior than in adults (figure 1). As a result, hyperextension of the neck may worsen obstruction of the upper airway.

- **Airway** – Because the airways of infants and children are smaller, they are more susceptible to obstruction from secretions, mucous, blood, vomitus, other debris, or a foreign body. Suctioning of the oropharynx and nasopharynx is essential to clearing the airway in infants and children with respiratory distress and failure (see "Airway management for pediatric anesthesia"). Relief of airway obstruction by a foreign body in infants and children requires separate management. (See "Emergency evaluation of acute upper airway obstruction in children".)

Anatomic differences between the pediatric and adult airway

Figure 1 - larger image below

- **Head** – The relatively larger occiput of the infant and young child causes passive flexion of the cervical spine in the supine position, which contributes to a tendency for the posterior pharynx to buckle during resuscitation. This can be prevented by maintaining the head in the **sniffing position**, which extends the neck and aligns the pharyngeal and tracheal axes. Placing a rolled towel under the shoulders of the infant may help to maintain proper positioning for airway management (picture 1) [1]. In children over two years old and adolescents, a towel under the occiput provides the necessary alignment (picture 2).

  Allow a spontaneously breathing child with upper airway obstruction to maintain an open airway with a position of comfort (picture 3).

- **Tongue** – The tongue is relatively larger compared with the oral cavity in infants and children than in adults. In an infant or child with a decreased level of consciousness, the tongue commonly falls back against the hypopharynx, resulting in airway obstruction [2,3].

EMERGENCY AIRWAY APPROACH

For the infant or child with respiratory distress or failure, initiate basic airway management while providing 100 percent supplemental oxygen [4]:

- **Assess the airway and breathing**

  - **Look** for movement of the chest or abdomen
  - **Listen** for air movement and sounds
  - **Feel** for air movement at the nose and mouth

- **Determine the status of the airway**

- **Clear** – Airway is patent for normal breathing
- **Maintainable** – Airway is not patent but can be opened and maintained with basic measures
- **Not maintainable** – Airway is not patent and cannot be opened and maintained without advanced measures

- **Open and maintain airway as needed with basic measures**

  - **Positioning** – Maintain the head in the sniffing position or allow a spontaneously breathing child to remain in a position of comfort.

  - **Noninvasive maneuvers** – Perform the head tilt-chin lift maneuver. At the same time, place the other hand on the child's forehead and gently tilt the head into a neutral position (figure 2) or, in the patient with possible C-spine injury, jaw-thrust maneuver (figure 3) with in-line C-spine stabilization (figure 4). (See 'Noninvasive relief of obstruction' below.)

  - **Suctioning** – Perform suctioning to remove secretions, mucous, blood, vomitus, and/or particulate matter from the nose and mouth.

  - **Airway adjuncts** – If the airway is not maintained with positioning and noninvasive maneuvers, place either an oropharyngeal airway (unconscious patient only) (figure 5) or nasopharyngeal airway (any patient) (figure 6). (See 'Airway adjuncts' below.)

  - **Basic life support** – If signs of total or near-total airway obstruction due to a foreign body are present, perform basic life support to relieve upper airway obstruction as described in the algorithm (algorithm 1).

- **Open and maintain airway with advanced measures** – If the airway cannot be opened or maintained with basic measures, immediately seek assistance from available airway specialists (eg, pediatric anesthesiology, pediatric otolaryngology, and/or pediatric critical care) and proceed to advanced airway management (algorithm 2). (See "The difficult pediatric airway for emergency medicine".)

Once the airway is opened with various basic airway management techniques as needed, assisted ventilation may be provided in infants and children with inadequate breathing using mouth-to-mouth, mouth-to-mouth-and-nose, and mouth-to-nose techniques, or with bag-mask ventilation. (See 'Assisted ventilation' below.)

NONINVASIVE RELIEF OF OBSTRUCTION

Head tilt-chin lift maneuver

- **Indications and contraindications** – The head tilt-chin lift maneuver is the preferred method for opening the airway in infants and children **except** when cervical spine injury is suspected [5,6].

  In infants and children with suspected cervical spine injury, the head tilt-chin lift maneuver should **not** be used prior to attempting to open the airway with a jaw thrust maneuver while maintaining in-line manual C-spine stabilization (figure 4) [6,7]. If the jaw thrust maneuver **does not** open the

airway, then the head tilt-chin lift maneuver should be attempted with continued C-spine stabilization [4,6].

- **Procedure** – Place the fingers of one hand under the mandible and lift upward to move the chin anteriorly. At the same time, place the other hand on the child's forehead and gently tilt the head into a neutral position (figure 2 and figure 7 and picture 4).

  With the thumb of the same hand, lightly depress the lower lip to open the mouth. Alternatively, place the thumb behind the mandibular incisors to gently lift the chin so that the mandibular central incisors are anterior to the maxillary central incisors.

  During the head tilt-chin lift procedure, **avoid** closing the mouth, pushing on the soft tissues under the chin, or hyperextending the neck (figure 8) [5], because any of these actions can cause airway obstruction.

Jaw thrust maneuver

- **Indications** – The jaw thrust maneuver is the preferred method for opening the airway in infants and children when there is concern for cervical spine injury [6]. During airway management, in-line manual cervical spine stabilization should also be maintained during airway maneuvers (figure 4).

  The jaw thrust maneuver is also useful for any patient when assisted ventilation with a bag-mask device is required. (See 'Bag-mask ventilation' below.)

- **Procedure** – With one hand on each side, grasp the angles of the mandible and move the mandible forward until the mandibular central incisors are anterior to the maxillary central incisors (figure 3 and picture 5).

SUCTIONING

For many infants and children with respiratory distress or failure, suctioning is essential to reestablish or maintain airway patency [4]. Because infants are typically obligate nasal breathers until about two to six months of age [8,9], suctioning of nasal secretions to remove airway obstruction in these patients can rapidly improve respiratory status.

- **Indications and contraindications** – Suctioning is indicated in all infants and children who have copious oral secretions, vomiting, or bleeding and who are showing signs of airway obstruction (eg, hypoxemia, respiratory distress, upper airway noise [snoring or stertor], and/or poor aeration despite adequate chest wall movement) or cannot properly protect their airway (eg, patients with altered mental status or difficulty swallowing).

  Care must be taken in all patients to avoid trauma to the oropharynx, nasal passages, or larynx; patients with bleeding disorders require particular attention. In patients with signs of facial or head trauma and possible cribriform plate disruption, avoid nasopharyngeal suctioning.

- **Procedure** – Suction the patient for brief intervals <30 seconds while monitoring breathing and oxygenation [10]:

  - **Oropharynx** – Using a tonsil tip suction device, gently perform suctioning by advancing it along the sides of the mouth and avoid the posterior pharynx to reduce the risk of gagging and vomiting. A flexible suction catheter may be used instead of a tonsil tip suction device for thin secretions.

    Use two tonsil tip suction devices for patients with copious bleeding or emesis.

  - **Nasopharynx** – Gently advance a flexible suction catheter with a bore size that easily passes into the nasal passage but is large enough to effectively clear nasal secretions. Occlude the side opening of the suction catheter and gently withdraw.

  Provide supplemental oxygen during intervals between suctioning.

- **Complications** – If vomiting occurs, rapidly place the patient on their side (recovery position; log roll trauma patients with possible spinal injury while maintaining spinal motion restriction (figure 9)) and continue to suction to clear the airway and avoid aspiration.

  If significant oxygen desaturation occurs during suctioning, stop and provide supplemental oxygen and, as needed, assisted ventilation. Once oxygen saturation has returned to a normal range, resume suctioning if needed.

AIRWAY ADJUNCTS

The oropharyngeal airway (OPA) or the nasopharyngeal airway (NPA) may be useful to improve ventilation, particularly when oropharyngeal structures, such as the tongue, are obstructing the airway [4,11].

Oropharyngeal airway — The OPA is composed of a flange, short bite-block segment, and curved body. It is designed to lift the tongue and hypopharyngeal soft tissues off the posterior pharynx to maintain a patent airway without damaging the laryngeal structures (picture 6) [4].

- **Indications and contraindications** – An OPA may be used in the **unconscious** infant or child to relieve airway obstruction caused by the tongue that has not been relieved by maneuvers (ie, head tilt-chin lift or jaw thrust). The OPA is optimally used as a bridge to recovery for a patient whose condition is expected to be temporary (such as a child who is postictal or recovering from sedation). However, prolonged tolerance of an OPA usually suggests the need for endotracheal intubation (ETI).

  Do **not** use an OPA if the infant or child has an intact cough and gag reflex. In addition, an OPA should **not** be used in a semiconscious infant or child because direct contact with the tongue and supraglottic structures may stimulate gagging and vomiting [4].

- **Sizing** – To estimate the correct OPA size, hold it along the side of the face orienting it with the flange at the patient's mouth (even with the incisors) and the tip directed towards the angle of the

mandible. The tip of an appropriately sized OPA should just reach the mandible (picture 7).

Limited evidence from a small observation study of children <12 years old undergoing cranial MRI suggests that this method is the most accurate for sizing of OPAs; however, it achieved optimal sizing (tip of OPA 1 cm from the tip of the epiglottis when in situ) in only 48 percent of patients as visualized on MRI [12]. Nevertheless, it outperformed several other landmark distances tested, including the corner of the mouth to the angle of the mandible. No patient had episodes of airway obstruction, vomiting, or laryngospasm during the procedure. Given the significant frequency of under-sized and over-sized OPAs placed in this study when using the incisor to mandible distance to estimate OPA size, it is important to verify proper function of the OPA after placement based on oxygenation, ventilation, and airway patency.

- **Procedure** – With a tongue blade, depress the tongue to the floor of the mouth, then gently insert the OPA in-line with the curve of the mouth and pharynx (figure 5). Depression of the tongue avoids inadvertently pushing the OPA into the base of the tongue and obstructing the airway.

  After the OPA is inserted, continue to monitor the infant or child for airway patency [13].

  Do **not** insert the OPA upside-down (ie, not in-line with the curve of the mouth and pharynx) and then rotate it 180 degrees into place because it may cause abrasion or injury to the tonsils or soft palate with bleeding that can lead to aspiration and/or push the tongue posteriorly causing airway obstruction.

- **Complications** – Selection of the appropriate OPA size and careful placement are necessary to use this device effectively and safely [4]. Complications of incorrect sizing include (figure 10):

  - Too large – Obstruction of the larynx, laryngeal injury, or laryngospasm
  - Too small – Obstruction of the airway caused by displacement of the tongue base posteriorly

Nasopharyngeal airway — The NPA is a flexible tube with a flange, which provides a conduit for airflow between the nares and the pharynx with minimal contact with the tongue [4].

- **Indications** – The NPA may be used in the **conscious or unconscious** infant or child to bypass airway obstruction caused by the tongue and pharyngeal soft tissues [4]. It is particularly useful to relieve obstruction caused by macroglossia or tonsillar hypertrophy in infants and children with normal mentation and respiratory function. The NPA is frequently helpful for relieving airway obstruction in infants and children with neurological impairment. In addition, an NPA minimizes nasopharyngeal trauma for patients who require frequent suctioning.

  The NPA is much less likely to induce vomiting than the OPA and can be used in infants and children with an intact cough and gag reflex.

- **Sizing** – We use the nostril to mandible length to estimate the length of the NPA before placement depending upon the type of NPA used:

  - **Adjustable flange** – For the NPA **with** an adjustable flange, choose the NPA with a bore that matches the size of the nares and passes easily into the nasopharynx. Set the length of

insertion by placing the NPA along the face from the nostril to the angle of the mandible and slide the flange to match the distance.

- **No adjustable flange** – For an NPA **without** an adjustable flange (picture 8), choose the NPA whose length is equal to the distance from the nostril to the angle of the mandible, then ensure that the bore of the NPA matches the size of the nostril and passes easily into the nasopharynx.

Several distances are proposed for estimating NPA length to ensure placement between the distal end of the soft palate and the epiglottis:

- Nostril to mandible [14]
- Nostril to tragus [15]
- Nostril to tragus minus 10 mm [16]

Of these, nostril to mandible has the most practical utility during emergency airway management while providing sufficient accuracy to ensure proper placement. A prospective study compared NPA placement with all three of the sizing methods above in 92 children undergoing cranial MRI [17]. An estimated length based upon the nostril-to-tragus distance minus 10 mm had the highest probability of acceptable placement (77 percent) compared with the distance from the nostril to mandible (59 percent) or nostril to tragus (28 percent). The nostril-to-tragus distance had a high chance of positioning the tip too close to the epiglottis (72 percent). Although nostril to tragus minus 10 mm may better estimate the acceptable length for an NPA, it may be more difficult to measure and implement during clinical care.

- **Procedure** – To place the NPA [10]:

  - Copiously lubricate the NPA with a water-soluble substance and, if time allows, instill a topical vasoconstrictor (eg, oxymetazoline 0.05%, 1 spray in each nostril).

  - Optional: During spontaneous breathing, occlude each nostril to determine which one is more patent; use this side for placement.

  - Gently insert the NPA along the floor of the nasopharynx in a posterior direction perpendicular to the plane of the face with the bevel facing the nasal septum (figure 6 and picture 9).

  - If the NPA does not pass readily, withdraw it and reattempt insertion in the other nostril.

  After the NPA is inserted, continue to monitor the infant or child for obstruction of the adjunct by secretions, mucous, blood, or vomitus as well as by the soft tissues of the pharynx. The inserted NPA may require frequent suctioning to maintain patency.

- **Complications**—To use an NPA effectively and safely, the clinician must select the appropriate size and place it carefully.

  If the NPA is too long, it may contact the larynx and/or lower pharynx and cause:

  - Bradycardia through vagal stimulation
  - Laryngeal injury with airway bleeding or swelling
  - Laryngospasm

- Vomiting with risk of aspiration
- Coughing

If the NPA bore is too large, it can cause:

- Injury to the nasal mucosa or adenoidal tissue and cause bleeding with risk for aspiration
- Pressure necrosis of the soft tissue and cartilage of the nose (alae nasi)

If the NPA bore is too small, it is easily obstructed by nasal secretions and will be ineffective.

ASSISTED VENTILATION

Once the airway is open and maintained, patients with inadequate breathing require assisted ventilation using bag-mask ventilation or, when bag-mask ventilation is not immediately available, mouth-to-mouth and/or nose techniques. If the airway cannot be opened or maintained to perform assisted ventilation, then the provider should obtain immediate expert airway assistance whenever available and proceed to advanced airway management (algorithm 2). (See "The difficult pediatric airway for emergency medicine".)

General principles — The following general principles of ventilation should be applied no matter which method of ventilation is used (see "Pediatric basic life support (BLS) for health care providers", section on 'Breathing'):

- **Airway** – Continue to maintain the airway with positioning, noninvasive maneuvers, suctioning, and airway adjuncts as described above. (See 'Emergency airway approach' above.)

  If the airway is not "maintainable" with these basic techniques, the provider should proceed to advanced airway management. (See "The difficult pediatric airway for emergency medicine".)

- **Breathing** – Deliver each breath over one second [7]. There should be a short pause between breaths to maximize oxygen content and minimize carbon dioxide concentration in the delivered breaths. The volume of each breath should be sufficient to see the chest wall rise.

- **Rescue breathing** – An infant or child with a heart rate ≥60/minute without normal breathing should receive one breath every two to three seconds (20 to 30 breaths per minute) [6].

- **Ventilation during cardiopulmonary resuscitation (CPR)** – For an infant or child requiring chest compressions (ie, pulseless or heart rate <60/minute), the timing of ventilation depends on whether or not the trachea is intubated and the number of rescuers (see "Pediatric basic life support (BLS) for health care providers", section on 'Basic life support approach'):

  - **Single rescuer** – Two breaths should be delivered at the end of every 30th compression.

  - **Two rescuers** – Two breaths should be delivered at the end of every 15th compression.

  - **Advanced airway** – Once the trachea is intubated, ventilations and compressions can be performed independently. Ventilations are given every two to three seconds (20 to 30 breaths per minute). Compressions are delivered at a rate of 100 to 120 per minute **without** pauses.

Gastric insufflation – Bag-mask ventilation and mouth-to-mouth/nose techniques may cause gastric insufflation, particularly if the breath is delivered too quickly or breaths are given too rapidly. This can interfere with effective ventilation by elevating the diaphragm and compromising lung expansion.

Minimize gastric insufflation by giving breaths slowly, so that an effective tidal volume is delivered at a lower inspiratory pressure [18]. When two rescuers are present, cricoid pressure is optional during bag-mask ventilation to compress the esophagus, thereby reducing gastric distension [6,19-23]. Evidence that compression of the esophagus decreases the risk of regurgitation and aspiration is limited. Care must be taken to not obstruct the airway if cricoid pressure is applied. (See "Rapid sequence intubation (RSI) in children for emergency medicine: Approach", section on 'Protection'.)

Mouth-to-mouth and/or nose — A barrier should be used for infection control whenever possible during mouth-to mouth, mouth-to-mouth-and-nose, and mouth-to-nose breathing [7].

- **Mouth-to-mouth breathing** – For children, the rescuer's mouth is placed over the victim's mouth to create a tight seal while the victim's nose is pinched closed (figure 11) [7].
- **Mouth-to-mouth-and-nose breathing** – For infants, the rescuer's mouth is placed over the victim's mouth and nose (figure 11).
- **Mouth-to-nose breathing** – This technique is an alternative to mouth-to-mouth-and-nose breathing for infants. When the mouth-to-nose technique is used, it is necessary for the rescuer to close the infant's mouth during rescue breathing.

Bag-mask ventilation — Health care providers who are properly trained can use a bag-mask device to provide adequate oxygenation and ventilation during pediatric resuscitation [7]. (See "Pediatric basic life support (BLS) for health care providers", section on 'Epidemiology and survival' and "Pediatric considerations in prehospital care", section on 'Basic airway management'.)

- **Indications** – Bag-mask ventilation may be provided to infants and children in the settings of respiratory distress and failure (including respiratory arrest) and cardiac arrest:
  - **Respiratory distress and failure** – Positive pressure ventilation should be provided to the infant or child with inadequate spontaneous breathing effort (ie, insufficient respiratory rate for age, chest expansion, or air movement). Bag-mask ventilation is successful in most infants and children in this setting with either an open airway or partial airway obstruction [24].
  - **Cardiac arrest** – During pediatric out-of-hospital cardiac arrest (OHCA), bag-mask ventilation appears to result in similar outcomes (eg, return of spontaneous circulation, intact neurologic survival and survival to hospital discharge) compared with placement of an advanced airway, including endotracheal intubation (ETI) and supraglottic airway (SGA such as a laryngeal mask airway), when transport times are short (<30 minutes). (See "Pediatric considerations in prehospital care", section on 'Basic airway management'.)

    During pediatric in-hospital cardiac arrest, data comparing rates of survival for bag-mask ventilation with ETI are limited but suggest that outcomes with bag-mask ventilation are at least

as good as ETI during the initial stages of CPR. (See "Pediatric basic life support (BLS) for health care providers", section on 'In-hospital cardiac arrest'.)

Ventilation bag — Bag-mask ventilation is performed with a bag-mask device consisting of a ventilation bag and a ventilation mask. Two types of ventilation bags are available, the self-inflating bag and the flow-inflating bag.

Self-inflating bag — The self-inflating bag provides a rapid means of ventilation and is preferred for assisted ventilation during initial resuscitation [4,6].

- **Size** – The self-inflating ventilation bag should have a minimum volume of 450 to 500 mL, even for newly born full-term infants [25-27]. For older children and adolescents, use an adult self-inflating bag (at least 1000 mL or larger) to ensure adequate ventilation with chest rise [4].

- **Testing** – Prior to use, the self-inflating bag should be checked for proper functioning, including against the characteristics and limitations of the particular device [25-28]:

  - Leaks: Occlude the patient outlet and squeeze the bag
  - Gas flow control valves: Check for proper functioning of the gas intake valve and the non-rebreather outlet valve
  - Pop-off valve: Ensure it can be easily disabled
  - Oxygen tubing: Check for secure connections to the bag-mask device and oxygen source
  - Oxygen flow: Set the flow rate to 10 to 15 L/minute into the bag and attach an oxygen reservoir to deliver 95 to 100 percent fraction of inspired oxygen (FiO_2)
  - Ventilation mask cuff: Ensure adequate size and seal (see 'Ventilation mask' below)

- **Oxygen delivery** – The self-inflating bag requires an oxygen reservoir to reliably deliver oxygen concentrations above 40 percent. This is because room air is entrained in the system when the bag reinflates. A minimum oxygen flow rate of 10 to 15 L/min is required to maintain an adequate oxygen volume in the reservoir [29]. With an oxygen flow rate of 15 L/min, oxygen concentrations between 95 and 100 percent can be delivered using a 2.5 L bag reservoir system [30].

- **Pop-off valve** – Self-inflating bags typically have a safety pop-off valve that reduces the risk of barotrauma by limiting peak inspiratory pressure (PIP) to between 35 and 45 cm H_2O. However, higher levels of PIP may be required to provide adequate tidal volume and oxygenation when airway resistance is high or lung compliance is poor [31]. In this setting, an automatic pop-off valve may result in delivery of insufficient tidal volume and can usually be disabled [32]. Whenever possible, an in-line manometer should be used to monitor PIP when the pop-off valve is disabled.

- **Mechanism** – When the self-inflating bag is released, the bag recoil mechanism reinflates the self-inflating bag from room air or, if available, from an oxygen source. During bag reinflation, the gas intake valve opens and allows the bag to fill. A dedicated expiratory valve may be present to prevent air entrainment into the device through the expiratory port, thereby diluting the FiO_2. During bag compression or patient inhalation, the gas intake valve closes, and a second valve (non-rebreathing outlet valve, most commonly duckbill or disc-type) opens to

permit gas flow to the patient (figure 12 and figure 13)[28]. During patient exhalation, the outlet valve closes, and the patient's exhaled gases are released to the atmosphere to prevent rebreathing of carbon dioxide.

- Advantages:
  - An oxygen source is not required for use (it can be used with room air if no oxygen is available).
  - It is easier to use (effective bag-mask ventilation can be performed more reliably by health care providers with variable levels of expertise using the self-inflating bag compared with the flow-inflating bag) [33,34].
- Disadvantages:
  - Supplementary "blow-by" oxygen cannot be reliably provided to the spontaneously breathing infant or child (this is due to the outlet valve, which may not open due to insufficient negative inspiratory pressure generated in the patient with inadequate respiratory effort to provide a continuous flow of oxygen to the mask).
  - FiO_2 is limited (<100 percent) unless an oxygen reservoir is added and allowed to fill.
  - A positive end-expiratory pressure (PEEP) valve (if present) cannot be used to provide continuous positive airway pressure (CPAP) during spontaneous breathing (this is due to the outlet valve, which opens only with high negative inspiratory pressure).
  - Feeling for changes in lung compliance and airway resistance is not easy (this is due to the stiffness of the bag).
  - Loss of ventilation mask seal is not readily apparent (this is due to the recoil mechanism, which always refills the bag after it is compressed).

Flow-inflating bag — The flow-inflating bag is used more often in in-hospital settings such as delivery rooms, intensive care units, and operating rooms. Effective use of the flow-inflating bag requires a trained provider who is able to adjust the flow of oxygen, adjust the PEEP valve, and ensure a proper seal with the ventilation mask [34]. Because of a longer time to first breath, a flow-inflating bag is typically not used in emergency settings.

- **Size** – The flow-inflating ventilation bag should have a volume of 500 mL in infants, 600 to 1000 mL in children, and 1000 mL or greater in older children and adolescents.
- **Testing** – Prior to use, test for:
  - Leaks: Provide flow to the circuit and occlude the patient outlet
  - Functioning gas flow values: Ensure that all valves, including PEEP valve and, if present, pop-off valve, are functioning properly
  - Oxygen tubing: Check connections to the bag-mask device and oxygen source
  - Oxygen flow: Set the flow rate to ensure rapid refilling of the bag (eg, 250 mL/kg/min up to 15 L/min)

- Manometer port: Ensure tight connection to manometer, or if a manometer is not being used, check that the port is plugged
- Ventilation mask cuff: Ensure adequate size and seal (see 'Ventilation mask' below)

- **Manometer** – The clinician should use adequate chest rise as a marker of effective ventilation. However, an in-line manometer may be used to monitor PIP and PEEP.

- **Mechanism** – Because the flow-inflating bag does not contain a non-rebreathing valve, the composition of inhaled gas is determined by the rate of fresh gas flow. The PEEP valve is adjusted to maintain volume in the reservoir bag necessary for appropriate positive pressure and allow an oxygen inflow rate sufficient to wash out exhaled gases. During ventilation, the fresh gas inflow is adjusted to at least 250 mL/kg/min. Increasing the oxygen inflow rate decreases the risk of rebreathing exhaled carbon dioxide.

  - Advantages:

    - Supplementary "blow-by" oxygen may be provided to the spontaneously breathing infant or child

    - FiO_2 is always 100 percent

    - PEEP or CPAP may be delivered with a tight-fitting ventilation mask by adjusting the PEEP usually to 5 to 10 cm H_2O

    - Feeling for changes in lung compliance and airway resistance is easy due to the compliance of the bag

    - Loss of ventilation mask seal is readily apparent with poor bag filling

  - Disadvantages:

    - Cannot provide ventilation without an oxygen source

    - Time to first breath is prolonged compared with a self-inflating bag

    - Requires more experience and training to use safely

- **Complications** – Complications from inappropriate PIP and PEEP include:

  - PIP – Excessive PIP can lead to barotrauma and is avoided by careful monitoring with the manometer.

  - PEEP – Inappropriate adjustment of the PEEP valve can lead to potential barotrauma and impedance to venous return with potential risk for hypotension (if the valve is opened too little, leading to higher resistance to flow out of the bag); inadequate ventilation rate and/or tidal volume (if the valve opening leads to slow refilling of the bag); and loss of ventilation rate and/or tidal volume (if the valve is opened too much, leading to bag collapse when compressed).

Ventilation mask — Effective bag-mask ventilation requires a ventilation mask that fits properly. The correct size is the smallest mask that completely covers the victim's mouth and nose without covering the eyes or overlapping the chin (picture 10) [4]. An airtight seal is required to deliver adequate inflation volume for effective ventilation. In older children and adolescents with facial hair, application of water or water-soluble lubricating jelly may be needed to obtain an adequate seal.

Technique — Bag-mask ventilation using the "E-C clamp technique" has been described by the American Heart Association and may be performed by a single rescuer or two rescuers [7]. For children with suspected cervical spine injury, airway management must be accomplished without moving the neck. In-line manual stabilization must be maintained. (See "Pediatric cervical spinal motion restriction", section on 'Motion restriction during airway management'.)

Single-rescuer E-C clamp technique

- **Procedure** – Utilizing the single-rescuer E-C clamp technique, the rescuer can optimally position the airway to deliver effective breaths while applying the ventilation mask tightly to the victim's face to avoid air leaks (picture 11). The technique is performed as follows [7]:

  - Positioning of the head requires two maneuvers (picture 2):

    - Neck flexion – The neck is flexed forward on the shoulders such that the external auditory canal is anterior to the shoulder. This may be accomplished in children by placing a towel or roll under the occiput. In infants, the towel must be placed under the shoulders to achieve this position because of a prominent occiput.

    - Head extension – The head is then extended on the neck such that the nose and mouth are pointing toward the ceiling.

  - The ventilation mask is placed on the child's face, with the narrowest portion of the mask over the bridge of the nose.

  - The little, ring, and middle fingers of one hand are then spread from the angle of the mandible forward along the mandible forming the "E." These fingers lift the jaw, pulling the face into the ventilation mask. The rescuer must be sure to keep the fingers on the mandible during assisted ventilation so that they do not compress the soft tissue of the inferior oropharynx.

  - Finally, the thumb and forefinger of the same hand are placed over the top of the ventilation mask in a "C" shape to squeeze it onto the face, forming a seal between the mask and the face.

E-C clamp technique

Picture 11 - larger image below

- Breaths are provided by using the other hand to compress the ventilation bag until the chest visibly rises. The rescuer should use only the force and tidal volume required to make the chest rise.

Two-rescuer E-C clamp technique

- **Procedure** – For some patients, two rescuers may be required to provide effective bag-mask ventilation (picture 12). In this situation, one rescuer uses both hands (each hand in the "E-C" configuration on either side of the face) to maintain the airway and hold the ventilation mask, while another rescuer compresses the ventilation bag. The rescuer holding the mask may also provide a jaw thrust to maintain the airway during ventilation. (See 'Jaw thrust maneuver' above.)

Two rescuer bag-mask ventilation

Picture 12 - larger image below

- **Indications** – Two-rescuer bag-mask ventilation may be necessary in the settings of:
  - Inadequate inflation pressure (ie, due to poor seal between the ventilation mask and the face)
  - Increased airway resistance (eg, acute severe asthma)
  - Poor lung compliance (eg, pneumonia or pulmonary edema) [35]
  - Cervical spine motion restriction (ie, suspected cervical spine injury)
- **Effectiveness** – The effectiveness of two-rescuer bag-mask ventilation was demonstrated in a prospective observational study in which greater peak pressures and mean tidal volumes per weight were generated in manikin models with two-rescuer, as compared with single-rescuer, bag-mask ventilation [36]. In a randomized crossover study performed on 60 children aged one through eight years with obstructive sleep apnea due to adenotonsillar hypertrophy, a two-handed airway technique during inhalational induction of anesthesia provided superior airway patency that was not influenced by anesthetic depth compared with a one-handed technique [37].

Children with suspected or confirmed COVID-19 — When providing bag-mask ventilation to children with suspected or confirmed COVID-19, health care providers should wear a respirator (eg, N95 mask) and other personal protective equipment (PPE) including eye protection (goggles or face shield), gloves, and gown and use an in-line high-efficiency particular air (HEPA) filter with a low dead space. Mouth-to-mouth/nose ventilation should be avoided [38-40].

MONITORING ADEQUACY OF VENTILATION

- **Indicators of adequate ventilation** – Among the clinical parameters, which should be constantly monitored as indicators of the adequacy of ventilation, visible chest rise with each breath is foremost. It must be assumed that if there is no chest motion during cardiopulmonary resuscitation (CPR), there is no ventilation. Other parameters include oxygen saturation, exhaled carbon dioxide,

heart rate, blood pressure, distal air entry, and patient response (eg, appearance, color, and level of agitation).

- **Causes of inadequate ventilation** – In the infant or child receiving bag-mask ventilation without an advanced airway, causes of inadequate ventilation include [4]:
  - Airway obstruction (due to congenital anomaly, trauma, burns, or foreign body in the airway (see "Airway foreign bodies in children"))
  - Insufficient ventilation pressure
  - Gastric insufflation
  - Bilateral pneumothorax
- **Troubleshooting inadequate ventilation** – Perform the following to troubleshoot inadequate bag-mask ventilation in the infant or child without an advanced airway:
  - Reopen the airway – With basic techniques (including suctioning, repositioning to ensure a sniffing position, reattempting maneuvers including further lifting the jaw during a jaw thrust, rechecking placement of an oropharyngeal airway [OPA] or nasopharyngeal airway [NPA]).
  - Treat foreign body upper airway obstruction – Management of upper airway foreign body is provided in the algorithm (algorithm 1) and discussed separately. (See "Emergency evaluation of acute upper airway obstruction in children".)
  - Increase ventilation pressure – By checking the bag-mask device, including verifying appropriate ventilation mask size, ensuring a tight mask seal, or disabling a pop-off valve on a self-inflating bag.
  - Assess for and treat gastric insufflation – By modifying ventilation technique (delivering a breath over one second then allowing adequate time for exhalation, decreasing tidal volume to just produce visible chest rise, ventilating at a slower rate to avoid excessive peak inspiratory pressure [PIP]), inserting a nasogastric tube or orogastric tube, or applying cricoid pressure.
  - Assess for and treat pneumothorax – Placement of thoracostomy tubes and catheters are discussed separately. (See "Thoracostomy tubes and catheters: Indications and tube selection in adults and children" and "Thoracostomy tubes and catheters: Placement techniques and complications".)

SOCIETY GUIDELINE LINKS

Links to society and government-sponsored guidelines from selected countries and regions around the world are provided separately. (See "Society guideline links: Basic and advanced cardiac life support in children" and "Society guideline links: Airway management in children".)

SUMMARY AND RECOMMENDATIONS

- **Emergency airway approach** – For the infant or child with respiratory distress or failure, initiate basic airway management while providing 100 percent supplemental oxygen:
  - **Assess airway for patency**
    - Look for movement of the chest or abdomen
    - Listen for air movement and sounds
    - Feel for air movement at the nose and mouth
  - **Determine the status of the airway**
    - Clear – Airway is patent for normal breathing
    - Maintainable – Airway is not patent but can be opened and maintained with basic measures
    - Not maintainable – Airway is not patent and cannot be opened and maintained without advanced measures
  - **Open and maintain airway with basic measures**
    - Positioning – Maintain the head in the sniffing position or allow a spontaneously breathing child to remain in a position of comfort.
    - Noninvasive maneuvers – Perform the head tilt-chin lift (figure 2) or, in the patient with possible C-spine injury, jaw-thrust maneuver (figure 3) with in-line C-spine stabilization (figure 4). (See 'Noninvasive relief of obstruction' above.)
    - Suctioning – Suction to remove secretions, mucous, blood, vomitus, and/or particulate matter from the nose and mouth.
    - Airway adjuncts – If the airway is not maintained with positioning and noninvasive maneuvers, place either an oropharyngeal airway (OPA; unconscious patient only) (figure 5) or nasopharyngeal airway (NPA; any patient) (figure 6). (See 'Airway adjuncts' above.)
    - Basic life support – If signs of total or near-total airway obstruction are present, perform basic life support to relieve upper airway obstruction as described in the algorithm (algorithm 1).
  - **Open and maintain airway with advanced measures** – If the airway cannot be opened or maintained with basic measures, immediately seek assistance from available airway specialists (eg, pediatric anesthesiology, pediatric otolaryngology, and/or pediatric critical care) and proceed to advanced airway management (algorithm 2). (See "The difficult pediatric airway for emergency medicine".)
- **Assisted ventilation** – For children with respiratory failure or cardiac arrest, provide bag-mask ventilation with supplemental oxygen (picture 11 and picture 12). The self-inflating bag provides a rapid means of ventilation and is generally preferred to a flow-inflating bag during emergency resuscitation (see 'Bag-mask ventilation' above). If bag-mask equipment is not immediately available, provide mouth-to-mouth and/or nose ventilation (figure 11). (See 'Mouth-to-mouth and/or nose' above.)

The following general principles of ventilation should be applied regardless of the method of ventilation used (see 'General principles' above and "Pediatric basic life support (BLS) for health care providers", section on 'Breathing'):

- **Airway** – Continue to maintain the airway with positioning, noninvasive maneuvers, suctioning, and airway adjuncts as described above. If the airway is not "maintainable" with these basic techniques, the provider should proceed to advanced airway management. (See "The difficult pediatric airway for emergency medicine".)
- **Breathing** – Deliver each breath over one second. There should be a short pause between breaths to maximize oxygen content and minimize carbon dioxide concentration in the delivered breaths. The volume of each breath should be sufficient to see the chest wall rise.
- **Rescue breathing** – An infant or child with a heart rate ≥60/minute without normal breathing should receive one breath every two to three seconds (20 to 30 breaths per minute).
- **Ventilation during cardiopulmonary resuscitation (CPR)** – For an infant or child requiring chest compressions (ie, pulseless or heart rate <60/minute), the timing of ventilation depends on whether or not the trachea is intubated and on the number of rescuers (see "Pediatric basic life support (BLS) for health care providers", section on 'Basic life support approach'):
  - **Single rescuer** – Two breaths should be delivered at the end of every 30th compression.
  - **Two rescuers** – Two breaths should be delivered at the end of every 15th compression.
  - **Advanced airway** – Once the trachea is intubated, ventilations and compressions can be performed independently. Ventilations are given every two to three seconds (20 to 30 breaths per minute). Compressions are delivered at a rate of 100 to 120 per minute **without** pauses.
- **Gastric insufflation** – Minimize gastric insufflation by giving breaths slowly, so that an effective tidal volume is delivered at a lower inspiratory pressure. During bag-mask ventilation with two rescuers present, cricoid pressure is optional to compress the esophagus and reduce gastric distension. However, discontinue cricoid pressure if it hampers effective ventilation. (See "Rapid sequence intubation (RSI) in children for emergency medicine: Approach", section on 'Cricoid pressure'.)

ACKNOWLEDGMENT

The editorial staff at UpToDate acknowledge Pamela Bailey, MD, who contributed to earlier versions of this topic review.

Use of UpToDate is subject to the Terms of Use.

REFERENCES

1. Alfahel W, Gopinath A, Arheart KL, et al. The Effects of a Shoulder Roll During Laryngoscopy in Infants: A Randomized, Single-Blinded, Crossover Study. Anesth Analg 2020; 131:1210.

2. Hudgel DW, Hendricks C. Palate and hypopharynx--sites of inspiratory narrowing of the upper airway during sleep. Am Rev Respir Dis 1988; 138:1542.
3. Abernethy LJ, Allan PL, Drummond GB. Ultrasound assessment of the position of the tongue during induction of anaesthesia. Br J Anaesth 1990; 65:744.
4. Pediatric Advanced Life Support Provider Manual, American Heart Association, Dallas 2020.
5. Bhalala US, Hemani M, Shah M, et al. Defining Optimal Head-Tilt Position of Resuscitation in Neonates and Young Infants Using Magnetic Resonance Imaging Data. PLoS One 2016; 11:e0151789.
6. Topjian AA, Raymond TT, Atkins D, et al. Part 4: Pediatric Basic and Advanced Life Support: 2020 American Heart Association Guidelines for Cardiopulmonary Resuscitation and Emergency Cardiovascular Care. Circulation 2020; 142:S469.
7. Berg MD, Schexnayder SM, Chameides L, et al. Part 13: pediatric basic life support: 2010 American Heart Association Guidelines for Cardiopulmonary Resuscitation and Emergency Cardiovascular Care. Circulation 2010; 122:S862.
8. Rodenstein DO, Perlmutter N, Stănescu DC. Infants are not obligatory nasal breathers. Am Rev Respir Dis 1985; 131:343.
9. Miller MJ, Martin RJ, Carlo WA, et al. Oral breathing in newborn infants. J Pediatr 1985; 107:465.
10. Scarfone RJ. Oxygen delivery, suctioning, and airway adjuncts. In: Textbook of Pediatric Emergency Procedures, 2nd edition, King C, Henretig FM (Eds), Wolters Kluwer | Lippincott, Williams & Wilkins, Philadelphia 2008. p.93.
11. King BR, King C, Coates WC. Critical procedures. In: APLS: The Pediatric Emergency Medicine Resource, 4th, Gausche-Hill M, Fuchs S, Yamamoto L (Eds), Jones and Bartlett, Sudbury 2004. p.692.
12. Nemeth M, Ernst M, Asendorf T, et al. Guedel oropharyngeal airway: The validation of facial landmark-distances to estimate sizing in children - Visualisation by magnetic resonance imaging (GUEDEL-I): A prospective observational study. Resuscitation 2023; 184:109702.
13. Kamlin COF, Schmölzer GM, Dawson JA, et al. A randomized trial of oropharyngeal airways to assist stabilization of preterm infants in the delivery room. Resuscitation 2019; 144:106.
14. Maconochie IK, Bingham R, Eich C, et al. European Resuscitation Council Guidelines for Resuscitation 2015: Section 6. Paediatric life support. Resuscitation 2015; 95:223.
15. European Paediatric Advanced Life Support Course Manual, European Resuscitation Council, Niel Belgium 2015.
16. Johnson M, Miskovic A, Ray S, et al. The nasopharyngeal airway: Estimation of the nares-to-mandible and nares-to-tragus distance in young children to assess current clinical practice. Resuscitation 2019; 140:50.
17. Nemeth M, Ernst M, Asendorf T, et al. Working with estimation-formulas to predict nasopharyngeal airway insertion depth in children: Looking at magnetic resonance images - A prospective observational study (WEND:LI-Study). Resuscitation 2021; 168:95.
18. Melker RJ. Asynchronous and other alternative methods of ventilation during CPR. Ann Emerg Med 1984; 13:758.

19. Kojima T, Laverriere EK, Owen EB, et al. Clinical Impact of External Laryngeal Manipulation During Laryngoscopy on Tracheal Intubation Success in Critically Ill Children. Pediatr Crit Care Med 2018; 19:106.
20. Kojima T, Harwayne-Gidansky I, Shenoi AN, et al. Cricoid Pressure During Induction for Tracheal Intubation in Critically Ill Children: A Report From National Emergency Airway Registry for Children. Pediatr Crit Care Med 2018; 19:528.
21. Salem MR, Wong AY, Mani M, Sellick BA. Efficacy of cricoid pressure in preventing gastric inflation during bag-mask ventilation in pediatric patients. Anesthesiology 1974; 40:96.
22. SELLICK BA. Cricoid pressure to control regurgitation of stomach contents during induction of anaesthesia. Lancet 1961; 2:404.
23. Moynihan RJ, Brock-Utne JG, Archer JH, et al. The effect of cricoid pressure on preventing gastric insufflation in infants and children. Anesthesiology 1993; 78:652.
24. Davis HW, Gartner JC, Galvis AG, et al. Acute upper airway obstruction: croup and epiglottitis. Pediatr Clin North Am 1981; 28:859.
25. Terndrup TE, Kanter RK, Cherry RA. A comparison of infant ventilation methods performed by prehospital personnel. Ann Emerg Med 1989; 18:607.
26. Field D, Milner AD, Hopkin IE. Efficiency of manual resuscitators at birth. Arch Dis Child 1986; 61:300.
27. Milner AD. Resuscitation at birth. Eur J Pediatr 1998; 157:524.
28. Dodds JM, Appelqvist DI, Paleologos MS, Downey RG. Variability in oxygen delivery with bag-valve-mask devices: An observational laboratory simulation study. Anaesth Intensive Care 2023; 51:130.
29. Finer NN, Barrington KJ, Al-Fadley F, Peters KL. Limitations of self-inflating resuscitators. Pediatrics 1986; 77:417.
30. Campbell TP, Stewart RD, Kaplan RM, et al. Oxygen enrichment of bag-valve-mask units during positive-pressure ventilation: a comparison of various techniques. Ann Emerg Med 1988; 17:232.
31. Driver BE, Atkins AH, Reardon RF. The Danger of Using Pop-Off Valves for Pediatric Emergency Airway Management. J Emerg Med 2020; 59:590.
32. Hirschman AM, Kravath RE. Venting vs ventilating. A danger of manual resuscitation bags. Chest 1982; 82:369.
33. Kanter RK. Evaluation of mask-bag ventilation in resuscitation of infants. Am J Dis Child 1987; 141:761.
34. Mondolfi AA, Grenier BM, Thompson JE, Bachur RG. Comparison of self-inflating bags with anesthesia bags for bag-mask ventilation in the pediatric emergency department. Pediatr Emerg Care 1997; 13:312.
35. Jesudian MC, Harrison RR, Keenan RL, Maull KI. Bag-valve-mask ventilation; two rescuers are better than one: preliminary report. Crit Care Med 1985; 13:122.
36. Davidovic L, LaCovey D, Pitetti RD. Comparison of 1- versus 2-person bag-valve-mask techniques for manikin ventilation of infants and children. Ann Emerg Med 2005; 46:37.

37. Choudhry DK, Brenn BR, Sacks K, et al. Comparative evaluation of one-handed versus two-handed mask holding techniques in children during inhalational induction of anesthesia: A randomized crossover study. Paediatr Anaesth 2021; 31:338.

38. Atkins DL, Sasson C, Hsu A, et al. 2022 Interim Guidance to Health Care Providers for Basic and Advanced Cardiac Life Support in Adults, Children, and Neonates With Suspected or Confirmed COVID-19: From the Emergency Cardiovascular Care Committee and Get With The Guidelines-Resuscitation Adult and Pediatric Task Forces of the American Heart Association in Collaboration With the American Academy of Pediatrics, American Association for Respiratory Care, the Society of Critical Care Anesthesiologists, and American Society of Anesthesiologists. Circ Cardiovasc Qual Outcomes 2022; 15:e008900.

39. Morgan RW, Atkins DL, Hsu A, et al. Guidance for Cardiopulmonary Resuscitation of Children With Suspected or Confirmed COVID-19. Pediatrics 2022; 150.

40. Kiss E, Garcia-Marcinkiewicz A, Zhong J, et al. Management of the Normal and Difficult Pediatric Airway: Unique Challenges in the Time of COVID-19. Curr Surg Rep 2023; 11:144.

Topic 6383 Version 34.0

GRAPHICS

Figure 1: **Anatomic differences between the pediatric and adult airway**

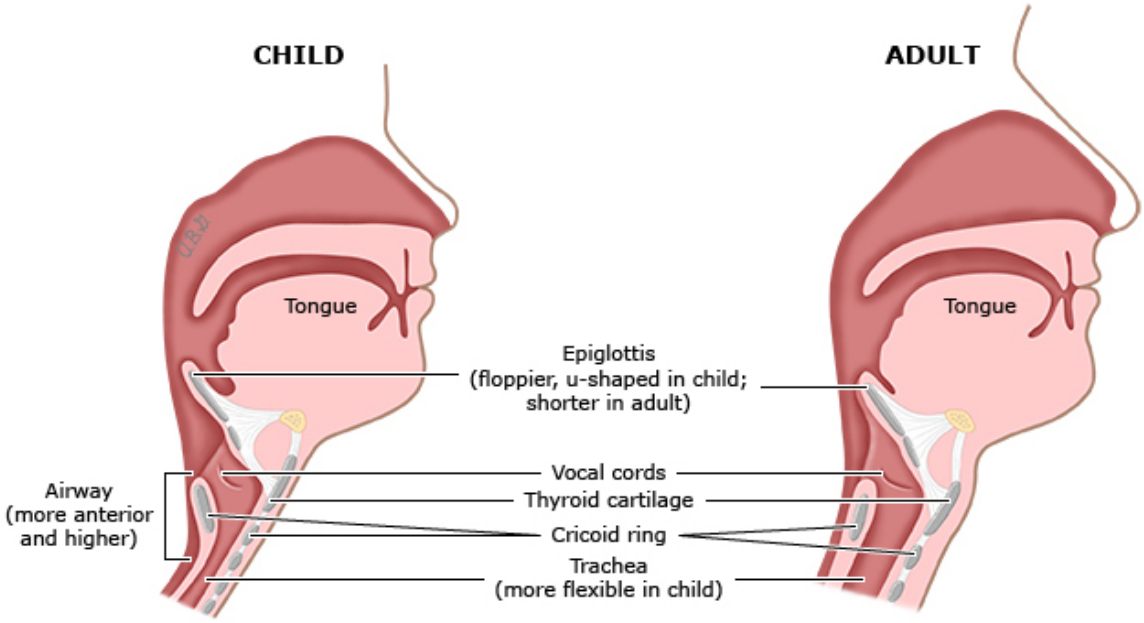

Relative to adults, children have:

- Large tongues relative to the size of the oral cavity
- Larger tonsils and adenoids
- A more superior location of the larynx in the neck
- A larger and floppy epiglottis
- The narrowest portion of the airway functionally occurring below the vocal cords

All of these differences make endotracheal intubation in children potentially more difficult than in adults.

Graphic 50850 Version 4.0

Picture 1: **Prominent occiput with pediatric airway obstruction**

Without support under the shoulders, the prominent occiput causes the head to flex forward and obstruct the airway in this sedated infant (A). With a shoulder roll in place, the airway is now in neutral position and clear (B).

Reproduced from: Santillanes, G, Gausche-Hill, M. Pediatric airway management. Emerg Med Clin North Am 2008; 26:961. Illustration used with the permission of Elsevier Inc. All rights reserved.

Graphic 78446 Version 2.0

Picture 2: **Proper positioning for ventilation and intubation for children older than two years of age**

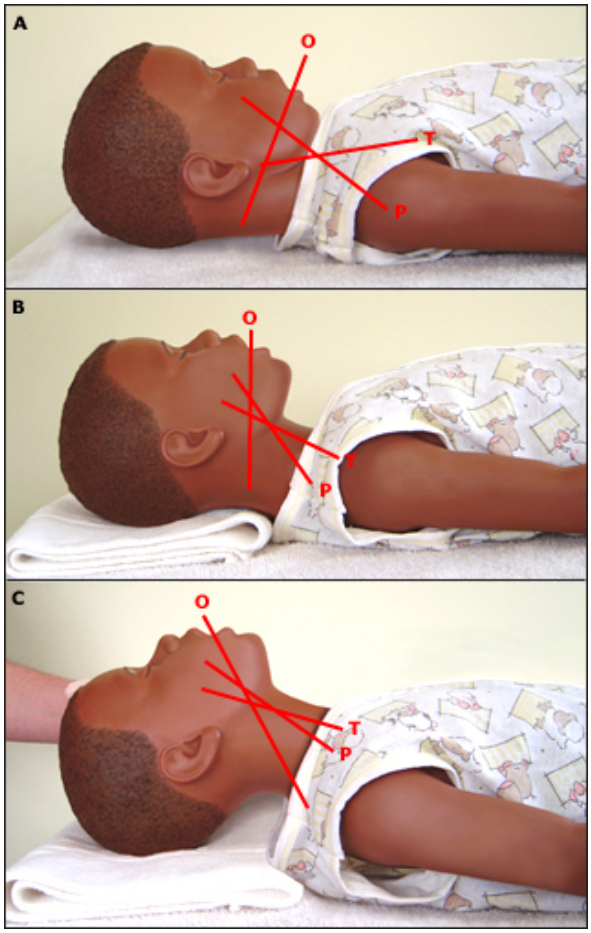

(A) The oral (O), tracheal (T), and pharyngeal (P) axes are in divergent planes.
(B) A towel under the occiput brings the external auditory canal anterior to the shoulder, aligning the T and P axes.
(C) The extension of the head on the neck, with the mouth and nose facing the ceiling, aligns the O axis with the T and P axes.

Graphic 69636 Version 6.0

Picture 3: **Child with classic presentation of acute epiglottitis**

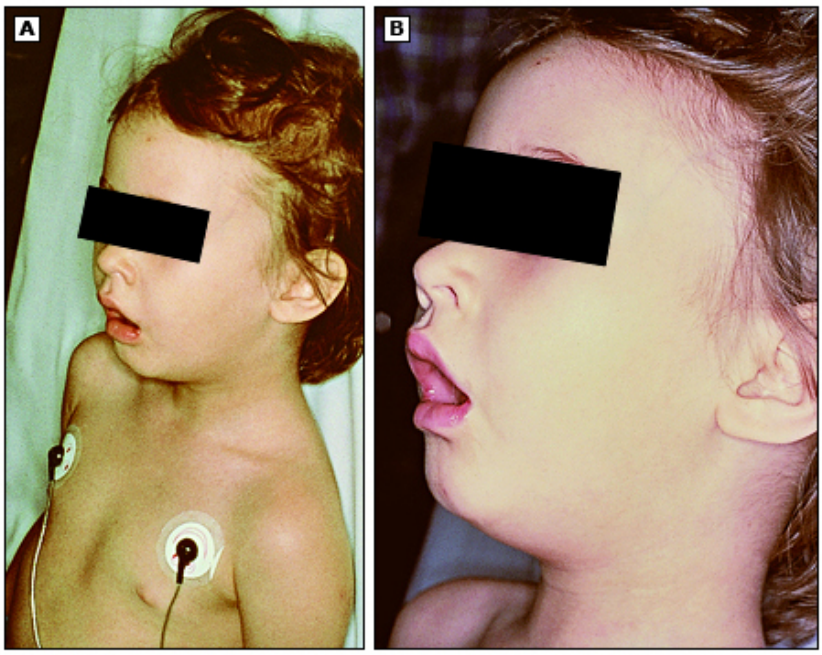

This 4-year-old girl has epiglottitis caused by *Haemophilus influenzae* type b.
(A) She prefers to sit and appears anxious.
(B) The child assumes the characteristic sniffing position to maximize the patency of her airway.

Reproduced with permission from: Fleisher GR, Ludwig W, Baskin MN. Atlas of Pediatric Emergency Medicine, Lippincott Williams & Wilkins, Philadelphia 2004. Copyright © 2004 Lippincott Williams & Wilkins.

Graphic 76538 Version 6.0

Figure 2: **Head tilt-chin lift in an infant**

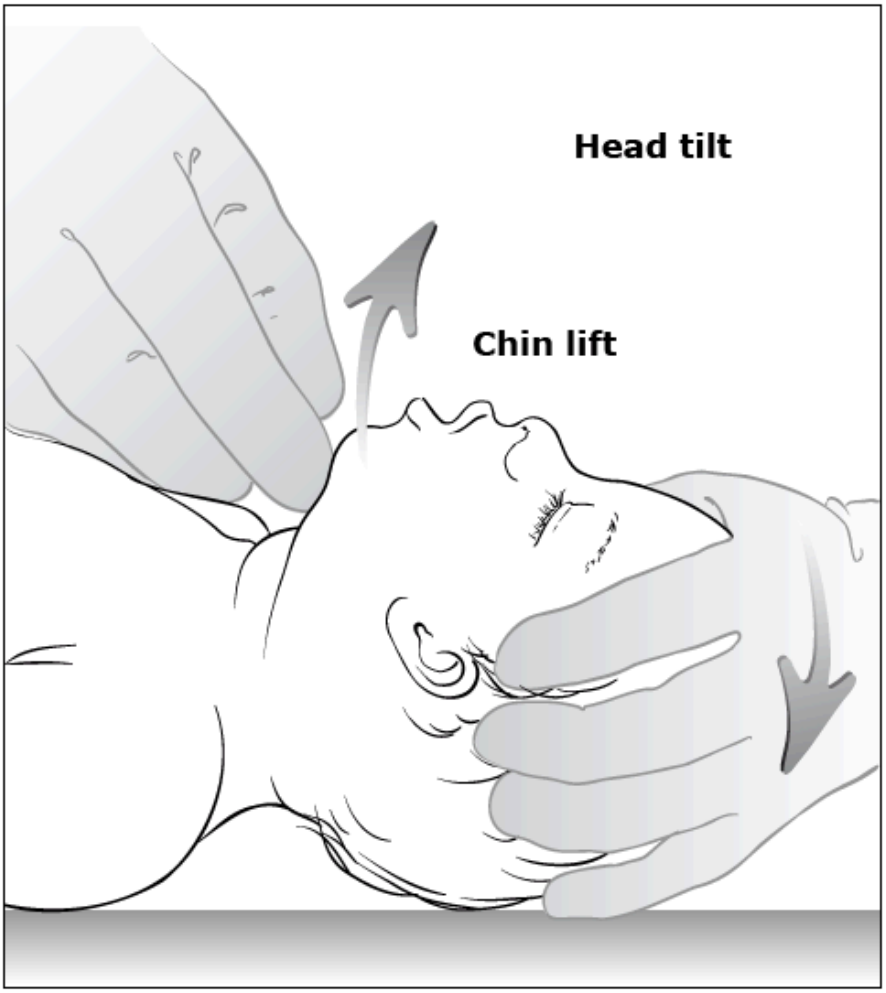

Head tilt-chin lift maneuver. Note that the fingers should not extend over the submental area, as this may produce airway obstruction.

From: McAneney CM. Basic life support. In: Textbook of Pediatric Emergency Procedures, 2nd ed, King C, Henretig FM (Eds), Lippincott Williams & Wilkins 2008. Copyright © 2008. Reproduced with permission from Wolters Kluwer Health. Unauthorized reproduction of this material is prohibited.

Graphic 139464 Version 1.0

Figure 3: **Jaw thrust maneuver in a child**

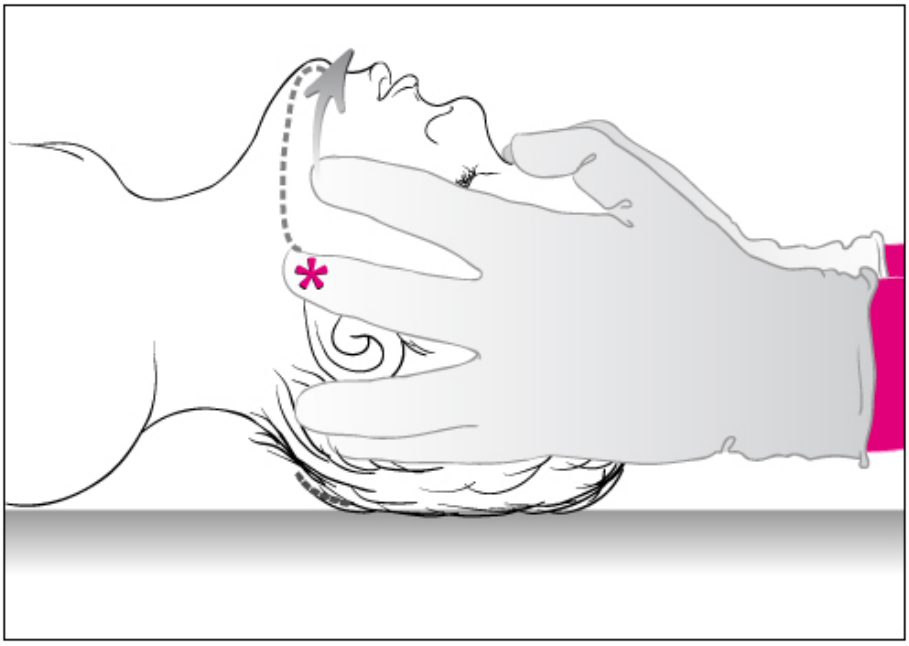

With the jaw thrust maneuver, the clinician can open the airway and limit neck motion. While maintaining the head and neck in a neutral position as shown, hook the middle finger of both hands under the angle of the jaw (asterisk) while providing countertraction with both thumbs on the forehead. Lift the mandible upward (arrow) to open the mouth and move the tongue anteriorly. The clinician can place their elbows on the surface above the patient's head to brace themselves and maintain the jaw thrust more comfortably.

From: McAneney CM. Basic life support. In: Textbook of Pediatric Emergency Procedures, 2nd ed, King C, Henretig FM (Eds), Lippincott Williams & Wilkins 2008. Copyright © 2008. Reproduced with permission from Wolters Kluwer Health. Unauthorized reproduction of this material is prohibited.

Graphic 139465 Version 1.0

Figure 4: **Manual stabilization of the pediatric spine**

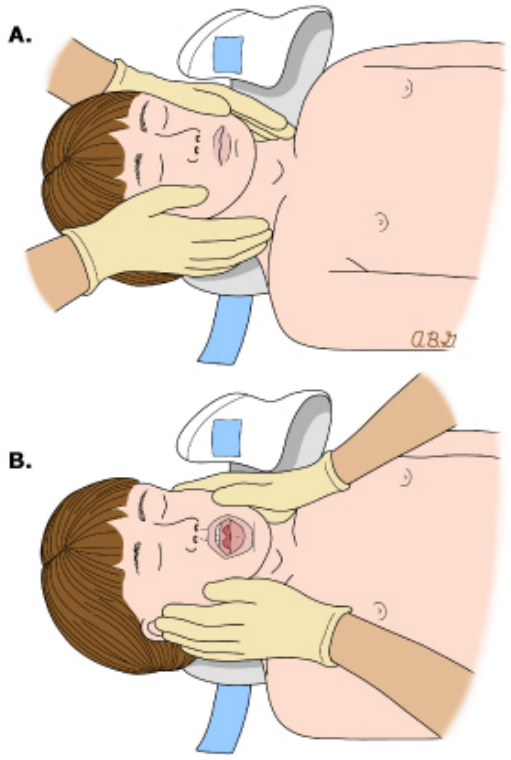

Graphic 80874 Version 5.0

Figure 5: **Oropharyngeal airway placement in a child**

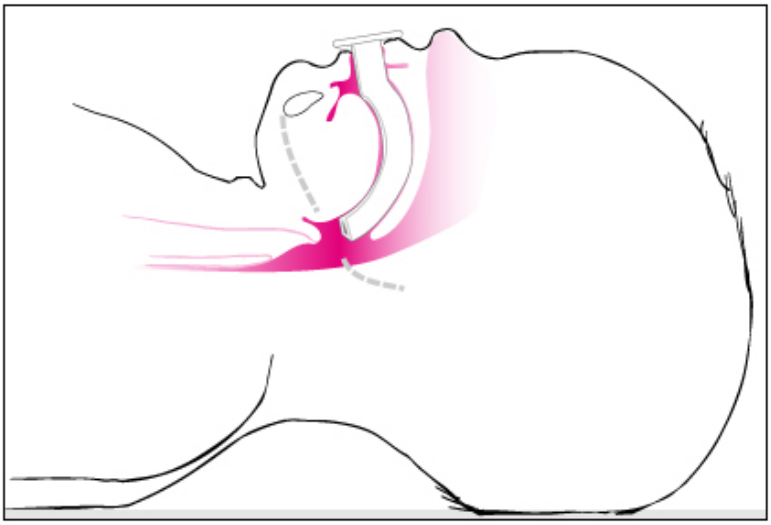

Proper position for an oropharyngeal airway.

From: Scarfone RJ. Oxygen delivery, suctioning, and airway adjuncts. In: Textbook of Pediatric Emergency Procedures, 2nd ed, King C, Henretig FM (Eds), Lippincott Williams & Wilkins 2008. Copyright © 2008. Reproduced with permission from Wolters Kluwer Health. Unauthorized reproduction of this material is prohibited.

Graphic 139462 Version 1.0

Figure 6: **Nasopharyngeal airway placement in a child**

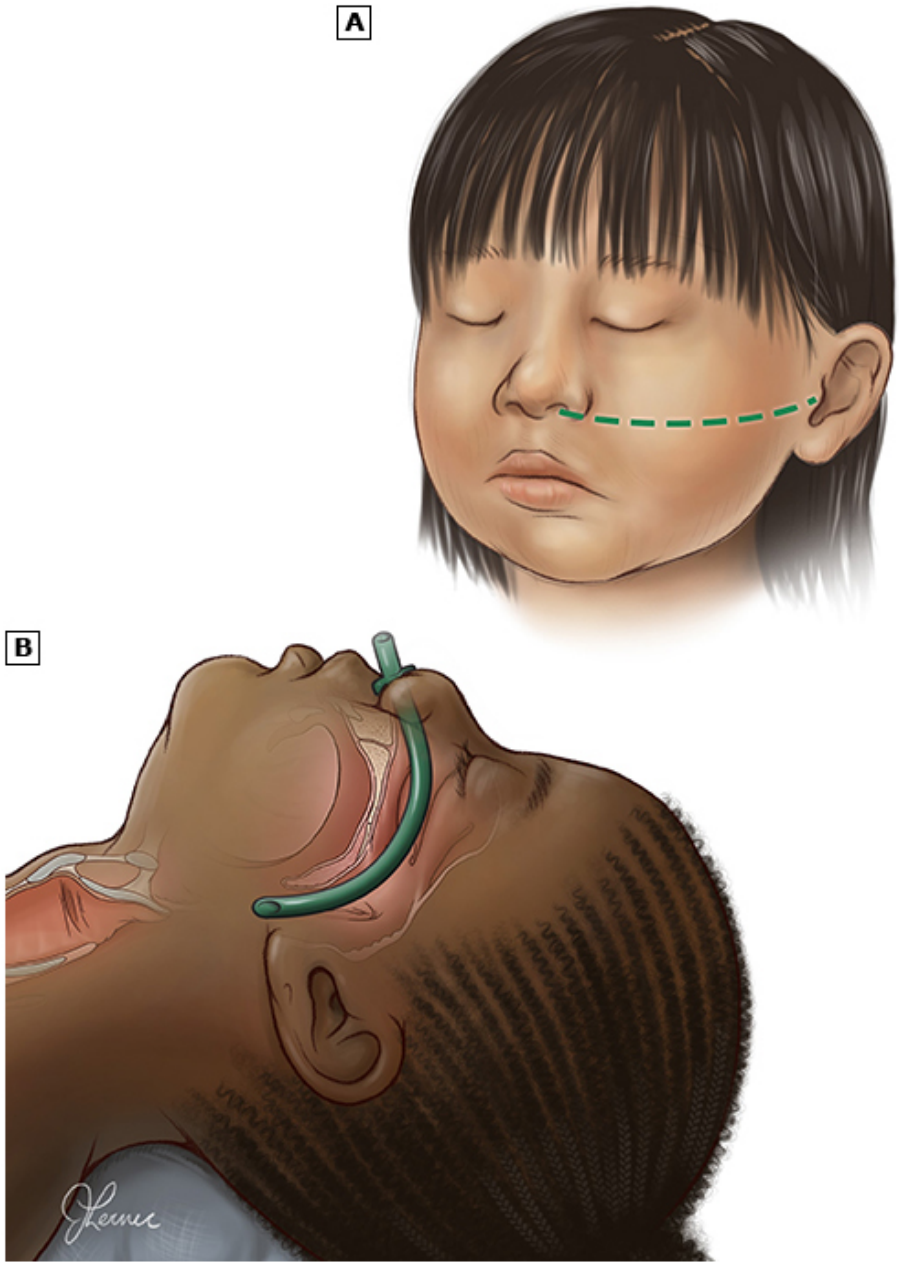

Insertion of a nasopharyngeal airway. Choose the NPA with a bore that is close to the size of the nares but passes easily into the nasopharynx. The airway can be sized properly by placing it adjacent to the child's face. The correct size will match the distance from the tragus of the ear to the nostril (A). After insertion, the tip of the airway should be positioned in the supraglottic region (B). Other proposed methods of estimating the correct length (not shown) include nostril to mandible and nostril to tragus minus 10 mm (for more, refer to UpToDate content on basic airway management in children).

Modified from: Scarfone RJ. Oxygen delivery, suctioning, and airway adjuncts. In: Textbook of Pediatric Emergency Procedures, 2nd ed, King C, Henretig FM (Eds), Lippincott Williams and Wilkins 2008.

Graphic 139463 Version 2.0

*

Algorithm 1: **Management of upper airway obstruction due to a foreign body in children**

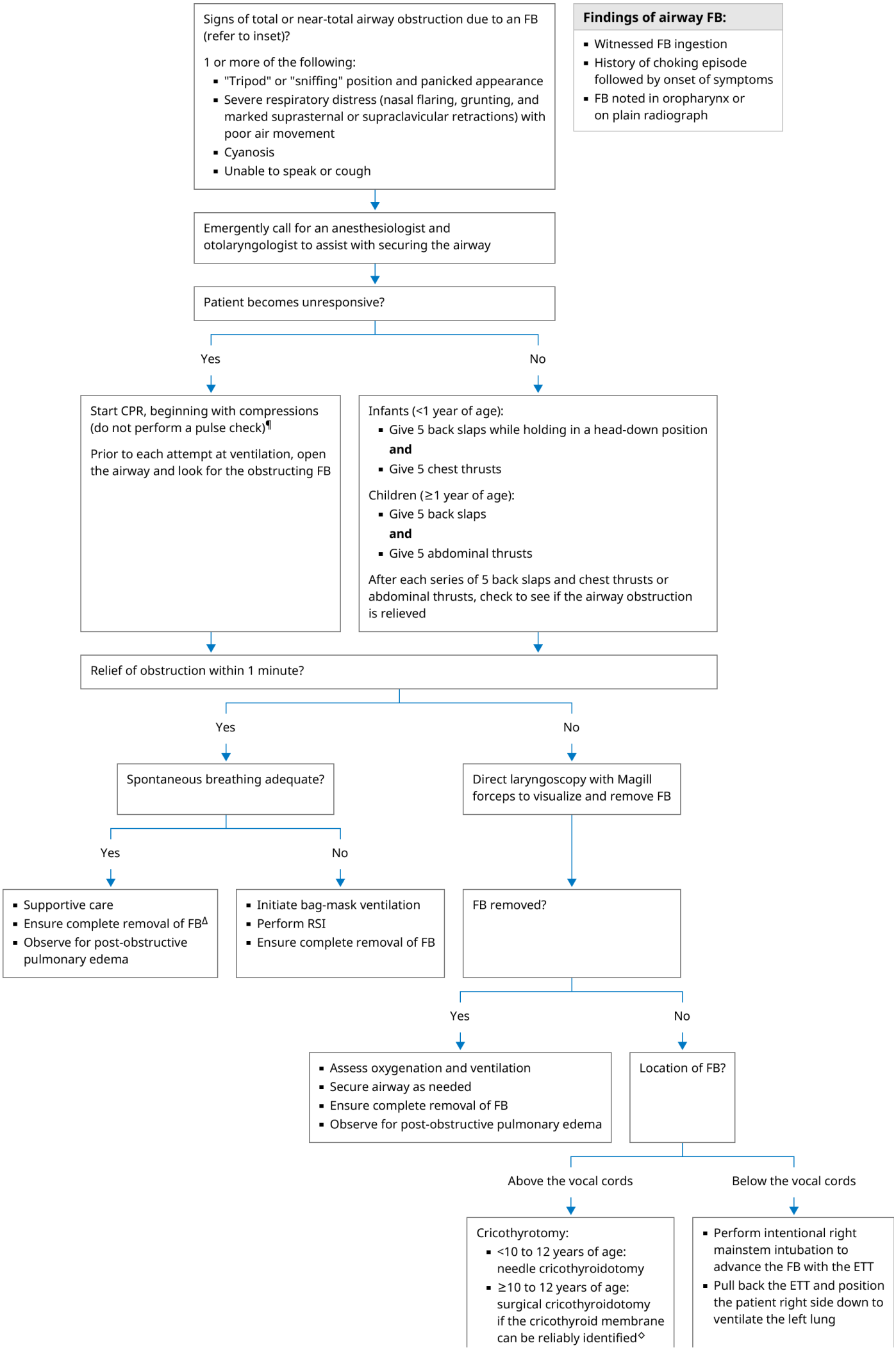
Signs of total or near-total airway obstruction due to an FB (refer to inset)?
1 or more of the following:
"Tripod" or "sniffing" position and panicked appearance
Severe respiratory distress (nasal flaring, grunting, and marked suprasternal or supraclavicular retractions) with poor air movement
Cyanosis
Unable to speak or cough
Findings of airway FB:
Witnessed FB ingestion
History of choking episode followed by onset of symptoms
FB noted in oropharynx or on plain radiograph
Emergently call for an anesthesiologist and otolaryngologist to assist with securing the airway
Patient becomes unresponsive?
Yes
No
Start CPR, beginning with compressions (do not perform a pulse check)¶
Prior to each attempt at ventilation, open the airway and look for the obstructing FB
Infants (<1 year of age):
Give 5 back slaps while holding in a head-down position
and
Give 5 chest thrusts
Children (≥1 year of age):
Give 5 back slaps
and
Give 5 abdominal thrusts
After each series of 5 back slaps and chest thrusts or abdominal thrusts, check to see if the airway obstruction is relieved
Relief of obstruction within 1 minute?
Yes
No
Spontaneous breathing adequate?
Direct laryngoscopy with Magill forceps to visualize and remove FB
Yes
No
Supportive care
Ensure complete removal of FBΔ
Observe for post-obstructive pulmonary edema
Initiate bag-mask ventilation
Perform RSI
Ensure complete removal of FB
FB removed?
Yes
No
Assess oxygenation and ventilation
Secure airway as needed
Ensure complete removal of FB
Observe for post-obstructive pulmonary edema
Location of FB?
Above the vocal cords
Below the vocal cords
Cricothyrotomy:
<10 to 12 years of age: needle cricothyroidotomy
≥10 to 12 years of age: surgical cricothyroidotomy if the cricothyroid membrane can be reliably identified◇
Perform intentional right mainstem intubation to advance the FB with the ETT
Pull back the ETT and position the patient right side down to ventilate the left lung

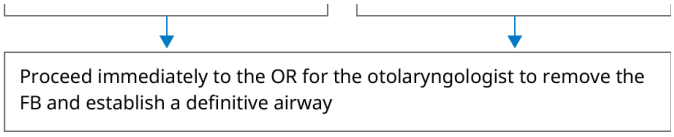

CPR: cardiopulmonary resuscitation; ETT: endotracheal tube; FB: foreign body; OR: operating room; RSI: rapid sequence intubation.

* The following findings suggest upper airway obstruction:
- Inspiratory stridor, wheezing, or stertor
- Suprasternal or supraclavicular retractions
- Prolonged inspiratory phase
- Oral mucosa or tongue swelling
- Drooling
- Dysphagia

Positions of comfort to help maintain airway patency in patients with severe obstruction:
- "Sniffing" position (neck is mildly flexed and head is mildly extended)
- Tripod position (leaning forward while bracing on the arms, with neck hyperextended and chin thrust forward)

¶ Refer to UpToDate algorithms and topics on pediatric basic life support for health care providers and FB obstruction.

Δ Refer to UpToDate topics on evaluation of upper airway obstruction in children.

◇ Needle cricothyroidotomy may be performed on patients of any age but is used instead of surgical cricothyroidotomy in infants and children up to 10 years of age because it is anatomically easier to perform with less potential damage to the larynx and surrounding structures. For description of the technique and performance of cricothyrotomy and transtracheal ventilation, refer to UpToDate topics on needle and surgical cricothyrotomy.

Graphic 55990 Version 7.0

Algorithm 2: **Difficult emergency airway management algorithm**

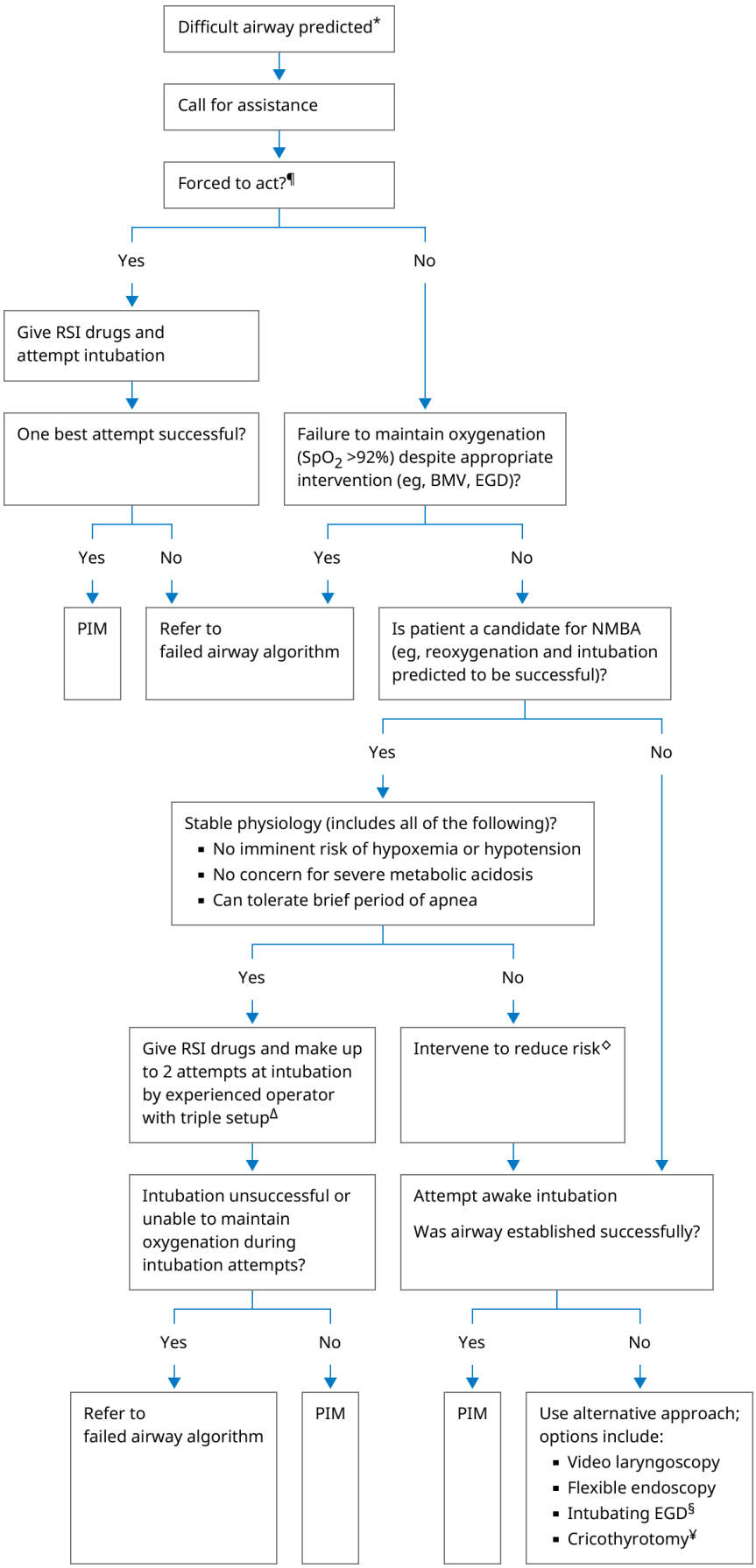

BMV: bag-mask ventilation; EGD: extraglottic airway device; NMBA: neuromuscular blocking agent; PIM: post-intubation management; RSI: rapid sequence intubation; SpO_2: oxygen saturation.

* Predicting the difficult airway is discussed in the UpToDate topic and includes assessment tools such as the LEMON mnemonic.

¶ This situation is further discussed in the UpToDate topic and includes, for example, a patient who is agitated and unable to cooperate, or a patient with rapidly progressing airway swelling.

Δ Triple setup implies a primary intubating plan is in place, followed by a nonsurgical rescue device (eg, EGD), and lastly a surgical rescue plan (most often an open surgical bougie-assisted cricothyrotomy).

◇ During RSI, physiologic derangements such as hypotension and hypoxemia increase the risk of cardiovascular collapse during the peri-intubation period. Possible mitigating interventions include the following:

- In the hypotensive patient – An intravenous bolus of isotonic fluid and push-dose vasopressors.
- In the hypoxemic patient – Administration of high-flow oxygen and apneic oxygenation.
- In the patient with severe metabolic acidosis – Treat the underlying etiology and perform awake technique if period of apnea contraindicated.

Refer to UpToDate topics on RSI for further detail.

§ The minimum age/weight limit for an intubating EGD is 12 yrs/30 kg.

¥ Needle cricothyrotomy may be performed on patients of any age but is preferable to surgical cricothyrotomy in infants and children up to 10 to 12 years of age because it is easier to perform with less potential damage to the airway. For older patients, surgical cricothyrotomy is typically chosen. For a description of these procedures, refer to UpToDate content on needle and surgical cricothyrotomy.

Adapted from Brown: The Walls Manual of Emergency Airway Management, 6th edition, Philadelphia, Wolters Kluwer, 2022 and The Difficult Airway Course (www.theairwaysite.com). Used with permission.

Graphic 140479 Version 6.0

Figure 7: **Head-tilt/chin-lift maneuver**

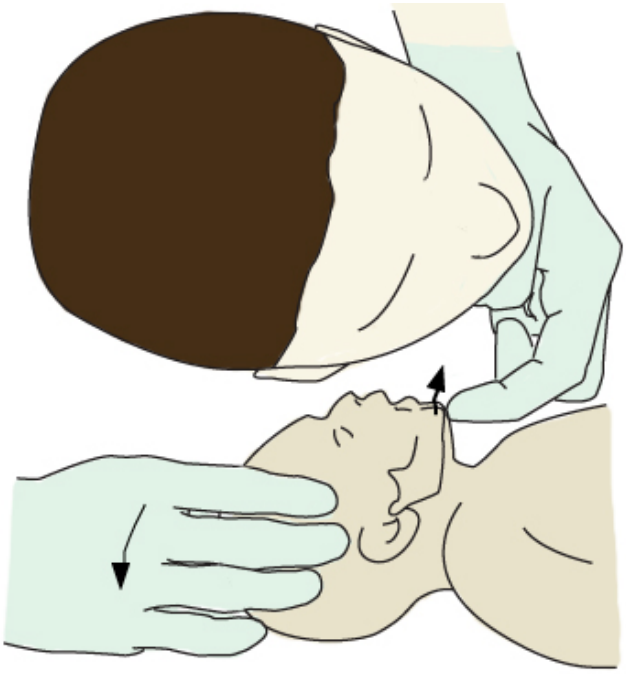

One of the rescuer's hands is used to tilt the head, extending the neck. The index finger of the rescuer's other hand lifts the mandible outward, raising the chin. Head tilt should not be performed if cervical spine injury is suspected.

Graphic 61533 Version 2.0

Picture 4: **Head-tilt/chin-lift maneuver**

To relieve upper airway obstruction, the clinician uses two hands to extend the patient's neck. While one hand applies downward pressure to the patient's forehead, the tips of the index and middle fingers of the second hand lift the mandible at the chin, which lifts the tongue from the posterior pharynx. The head-tilt/chin-lift maneuver may be used in any patient in whom cervical spine injury is **NOT** a concern.

Graphic 70710 Version 7.0

Figure 8: **Airway changes with hyperextension**

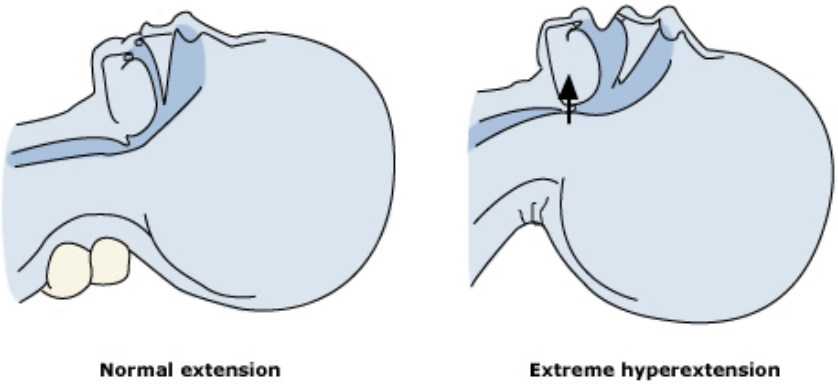

During the chin-lift procedure, care must be taken to avoid hyperextending the neck, which may cause airway obstruction (arrow).

Graphic 73382 Version 3.0

Picture 5: **Jaw-thrust maneuver**

The jaw-thrust maneuver is used to relieve upper airway obstruction by moving the tongue anteriorly with the mandible, minimizing the tongue's ability to obstruct the airway. With the patient supine and the clinician standing at the head of the bed, the technique is performed by placing the heels of both hands on the parieto-occipital areas on each side of the patient's head, then grasping the angles of the mandible with the index and long fingers, and displacing the jaw anteriorly. The jaw-thrust maneuver may be used in the patient in whom cervical spine injury is a concern.

Graphic 51547 Version 6.0

Figure 9: **Log-roll procedure**

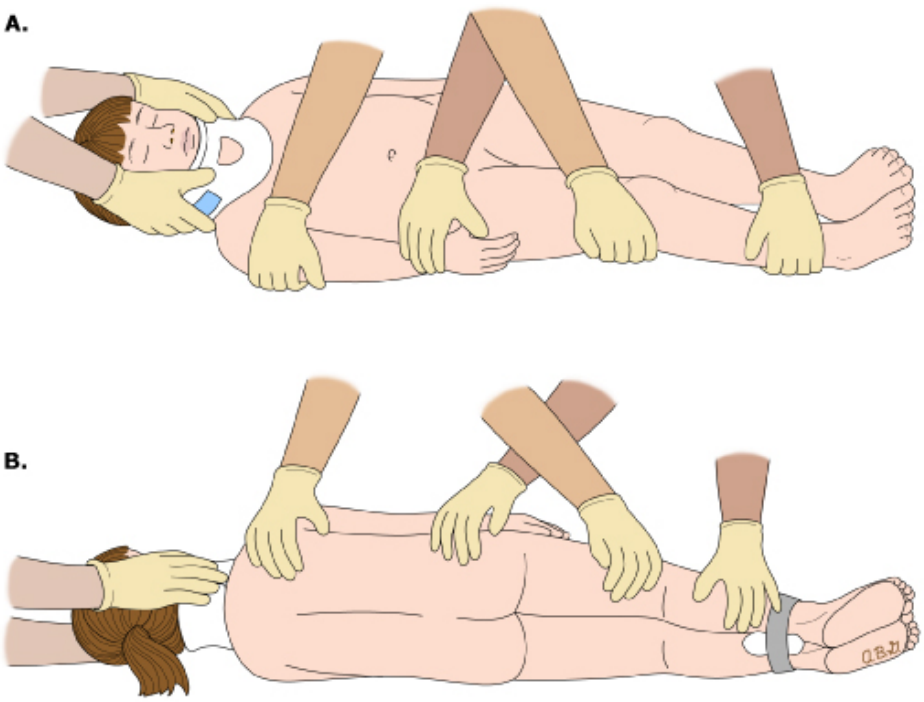

Graphic 60409 Version 2.0

Picture 6: **Oropharyngeal airways**

Graphic 50230 Version 2.0

Picture 7: **Oropharyngeal airway sizing**

A rough method for choosing the correct oropharyngeal airway (OPA) size is to hold the airway beside the patient's mandible, orienting it with the flange at the patient's mouth and the tip directed toward the angle of the mandible. The tip of an appropriately sized OPA should just reach the angle of the patient's mandible.

Graphic 77645 Version 3.0

Figure 10: **Complications of improper sizing of oral airway**

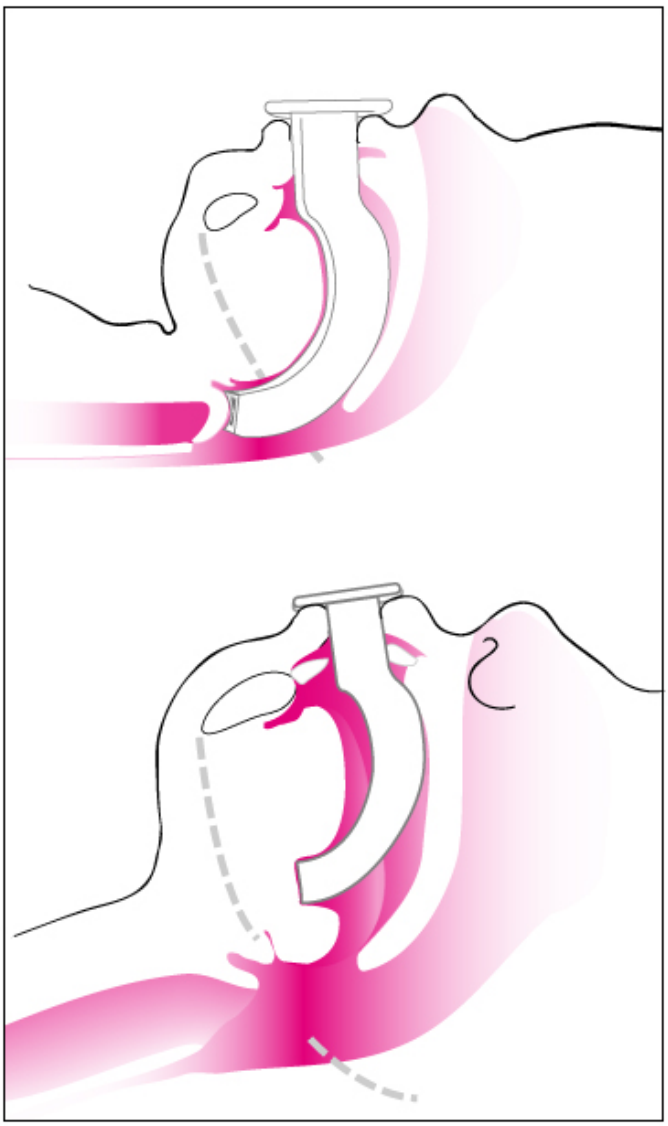

Improperly sized oropharyngeal airways. An oropharyngeal airway that is too large will displace the epiglottis inferiorly over the glottic opening. An airway that is too small will impinge on the tongue, displacing it posteriorly into the hypopharynx.

From: Scarfone RJ. Oxygen delivery, suctioning, and airway adjuncts. In: Textbook of Pediatric Emergency Procedures, 2nd ed, King C, Henretig FM (Eds), Lippincott Williams & Wilkins 2008. Copyright © 2008. Reproduced with permission from Wolters Kluwer Health. Unauthorized reproduction of this material is prohibited.

Graphic 139466 Version 1.0

Picture 8: **Nasopharyngeal airways without an adjustable flange**

For an NPA without an adjustable flange, the correct size is more accurately determined by the length rather than bore of the adjunct. The distance from the nostril to the tragus has been shown to correlate well with the length from the nostril to the vocal cords in normal infants and children and is our preferred method for sizing. Alternatively, the distance from the nostril to the mandible may be used. However, the accuracy of this method has not been studied.

Graphic 69419 Version 3.0

Picture 9: **Nasopharyngeal airway insertion**

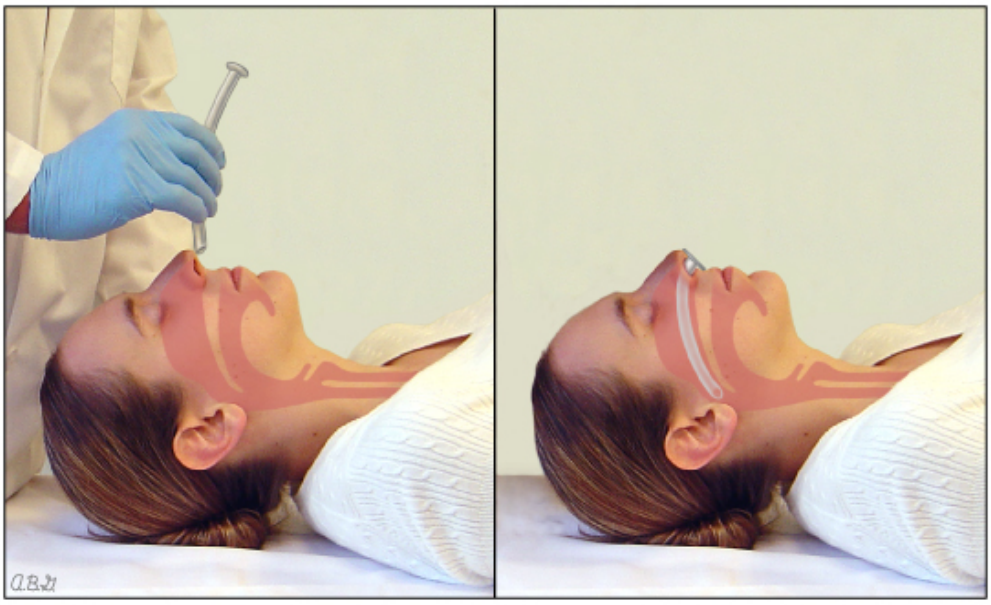

The nasopharyngeal airway (NPA) should be coated with water-soluble lubricant or anesthetic jelly. The device is then inserted along the floor of the naris into the posterior pharynx behind the tongue. Clinicians should note that the floor of the naris inclines in a caudad orientation approximately 15 degrees. The tube can be rotated slightly if resistance is encountered.

Graphic 79849 Version 4.0

Figure 11: **Rescue breathing in a child and infant**

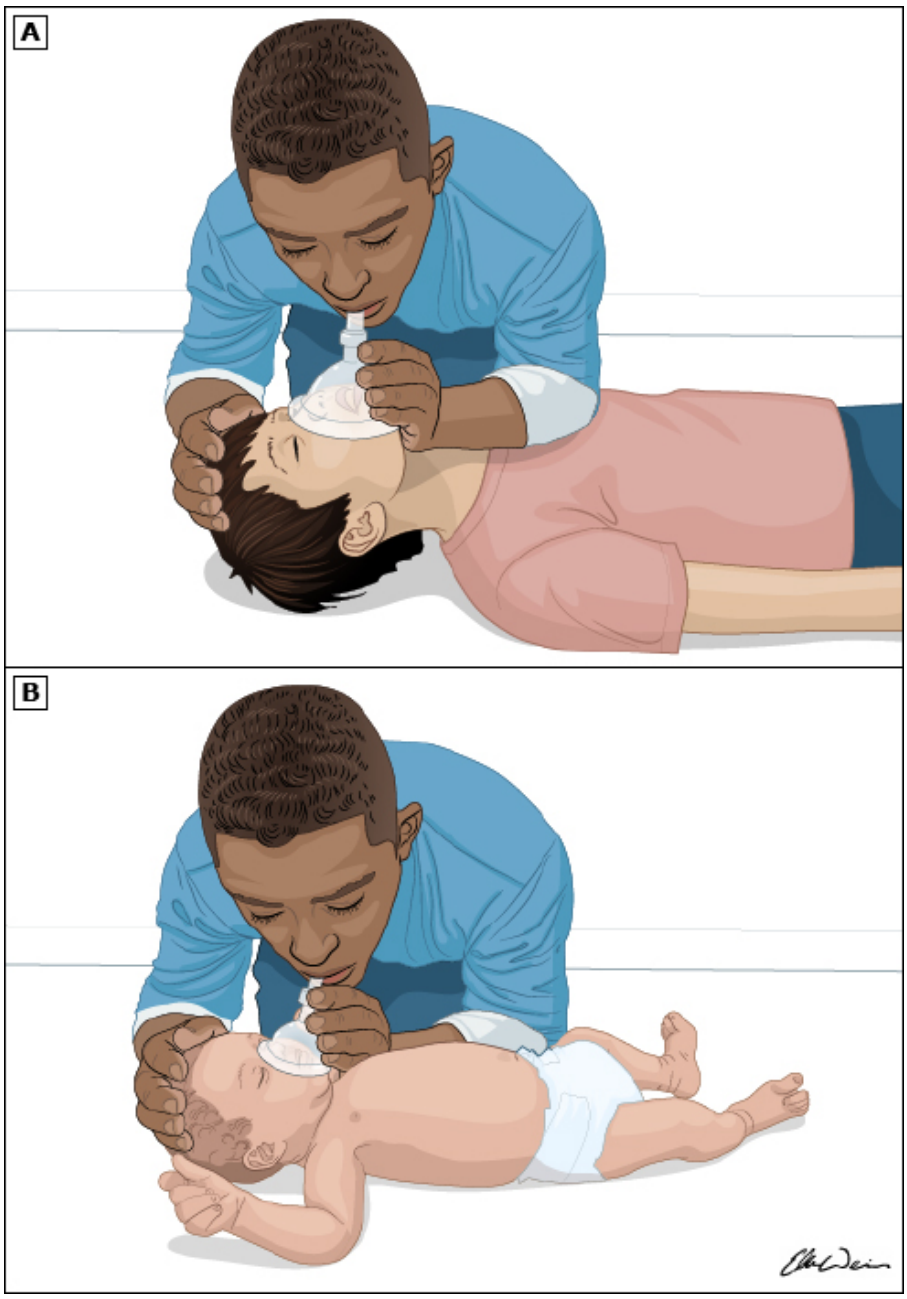

(A) Rescue breathing for the child.

(B) Rescue breathing for the infant.

Graphic 139467 Version 2.0

Figure 12: **Self-inflating bag-mask device with duckbill nonrebreather valve**

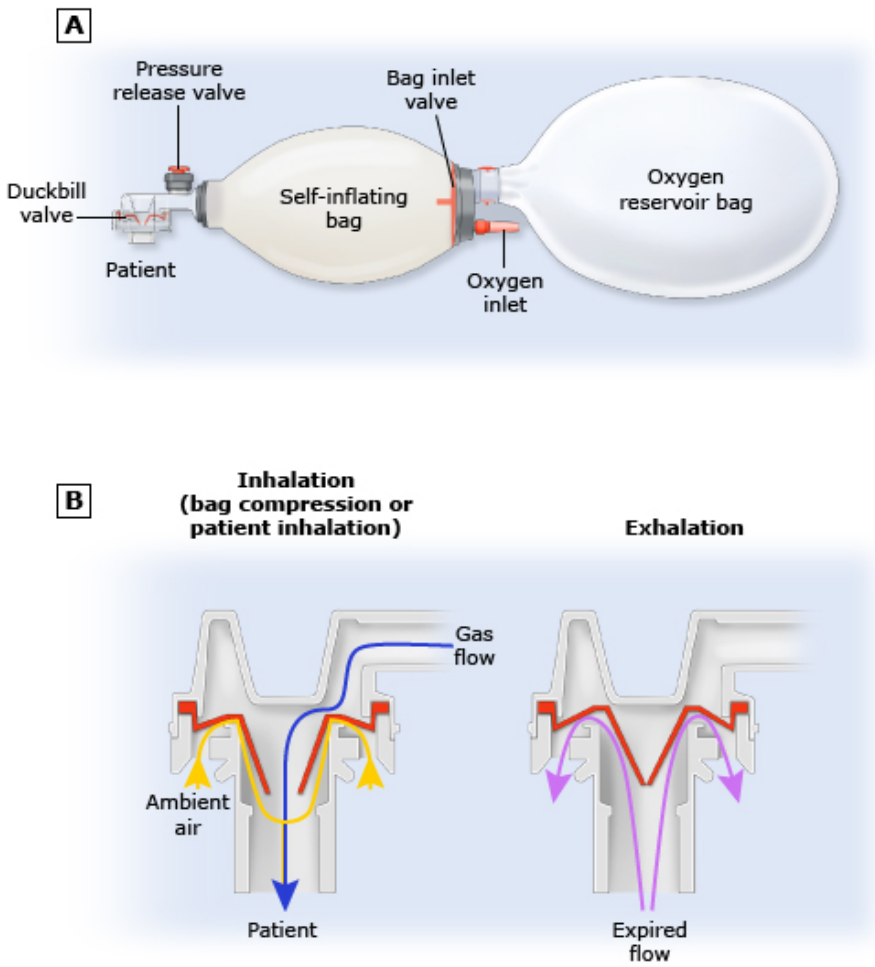

(A) The components of the self-inflating bag with a unidirectional, duckbill, nonrebreather outlet valve.

(B) The duckbill valve is a thin, flexible diaphragm with two protruding leaflets. During bag compression (inhalation), the leaflets open, allowing gas to flow from the device to the patient. During patient exhalation, the leaflets return to the original closed position and the valve relaxes off the expiratory port allowing expired gas to exit. This mechanism permits delivery of 95 to 100% oxygen when oxygen flow to the device is 10 to 15 L/minute.

During spontaneous patient inhalation, the leaflets are opened by sufficient negative inspiratory pressure generated by the patient and assisted by forward flow of fresh gas. The amount of air entrainment from the expiratory port is determined by the opening pressure of the valve and the relative resistance to airflow through the valve and expiratory port. If no expiratory valve cap is present as is the case in this figure, then delivery of oxygen during spontaneous breathing can be significantly less than 100%.

Graphic 145765 Version 1.0

Figure 13: **Self-inflating bag-mask device with disc-type nonrebreather valve**

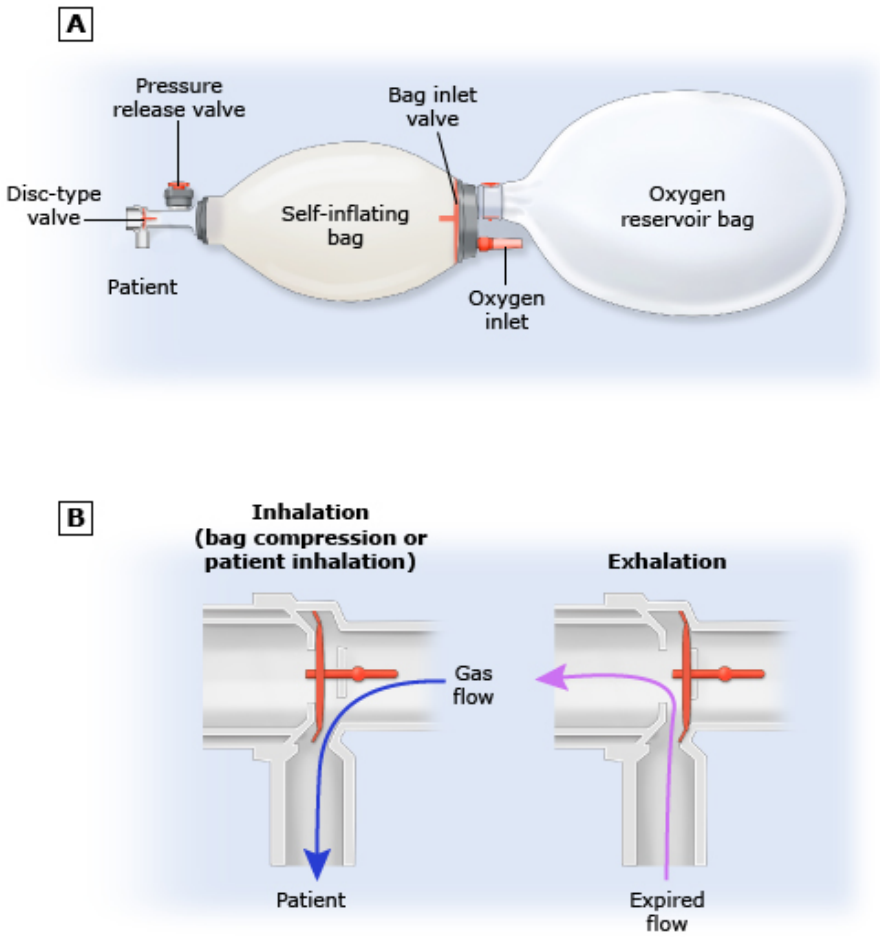

(A) The components of the self-inflating bag with a unidirectional, disc-type, nonrebreather outlet valve.

(B) The disc-type valve is a single silicone disc. During bag compression or spontaneous patient inhalation, the disc retracts against the expiratory port allowing gas to flow from the device to the patient while closing the expiratory port to air entrainment. This mechanism permits the delivery of 95 to 100% oxygen when oxygen flow to the device is 10 to 15 L/minute. During bag release or patient exhalation, the disc returns to the original closed position, allowing gas to exit through the expiratory port and preventing re-entry of expired air into the device.

Graphic 145766 Version 1.0

Picture 10: **Choosing the proper size pediatric mask**

The correct size mask is the smallest size that completely covers the child's nose and mouth (photos on left), without covering the eyes or overlapping the chin (photos on right).

Graphic 76143 Version 5.0

Picture 11: **E-C clamp technique**

The hand is positioned so that the little, ring, and middle fingers are spread over the mandible from the angle of the jaw forward towards the chin in the configuration of the letter "E". The jaw is then lifted, pulling the face into the mask. The thumb and forefinger are placed over the mask in the shape of the letter "C". The mask is squeezed onto the face and a seal is formed between the mask and the face.

Graphic 55539 Version 7.0

Picture 12: **Two rescuer bag-mask ventilation**

Two rescuers may be necessary to provide ventilation. One rescuer may need both hands to open the airway and make the seal between the child's face and the mask. The second rescuer is then needed to provide positive pressure ventilation.

Graphic 72516 Version 5.0

Contributor Disclosures

Mark E Ralston, MD, MPH No relevant financial relationship(s) with ineligible companies to disclose. **Mark I Neuman, MD, MPH** No relevant financial relationship(s) with ineligible companies to disclose. **James F Wiley, II, MD, MPH** No relevant financial relationship(s) with ineligible companies to disclose.

Contributor disclosures are reviewed for conflicts of interest by the editorial group. When found, these are addressed by vetting through a multi-level review process, and through requirements for references to be provided to support the content. Appropriately referenced content is required of all authors and must conform to UpToDate standards of evidence.

Conflict of interest policy

→